

## Ventricular Septal Defect

### What is it?

- A hole in the wall (septum) that separates both ventricles.
- It is the most common congenital heart malformation at birth.
- Mostly diagnosed and where indicated it is treated before adulthood.
- May spontaneously close without treatment.
- Can be a single defect or a component of complex defects such as TOF, TGA etc.

### How is it diagnosed?

- Transthoracic echocardiogram, transoesophageal echo.
- Cardiac MRI.
- Cardiac catheterisation.

### How does it affect the heart?

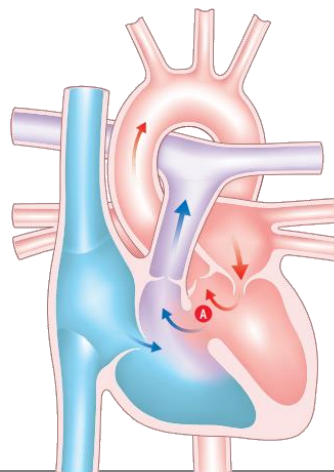
- LV volume overload and heart failure secondary to left to right shunt.
- Double chambered right ventricle can develop over time.
- Most patients who have VSD closure in childhood with no LV volume overload will remain asymptomatic.
- Risk of arrhythmia.
- Development of complete AV block.
- Risk of endocarditis.

### What is the treatment/long term management?

- Can be closed either surgically or via transcatheter device (depends on location within septum/patient risk factors).
- For small uncomplicated VSDs, closure is usually avoided.

### What is the follow up?

- Regular follow up post VSD closure, then 3-5 year follow up once stable.
- 3-5 year follow up for untreated small VSDs.



**A** Ventricular septal defect