

Learning from clinical incidents: ACHD

Dr Stephanie Curtis
Consultant ACHD Cardiologist
University Hospitals Bristol



Michael, 37

Amiodarone induced thyrotoxicosis

Pulmonary atresia/VSD

Surgical repair 1981

Conduit replacement (bifurcation homograft) 1995

Residual VSD and bilateral branch PA stenosis

LPA and RPA stents 1999

VT - ICD implantation 2004 (started Amiodarone), infected and removed 2010

Biventricular impairment

Severe tricuspid regurgitation

Atrial fibrillation

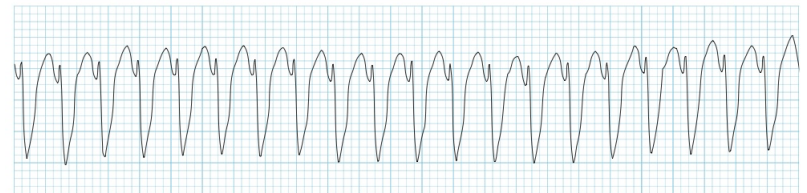
Hepatitis C positive - following blood transfusion

CKD Stage 2 (inc dialysis post cellulitis)

Recurrent atrial tachycardia

Declined transplant

VT storm



Martin, 39

Transposition of the great arteries

Mustard repair 1979

Severe systemic right ventricular impairment

Severe tricuspid regurgitation

Atrial tachycardia 2014 requiring cardioversion

ICD

CKD Stage 2

Gout

Smoker

Recurrent UTIs

Recurrent admissions for heart failure

Medication:

Lisinopril 10 mg od

Bisoprolol 3.75 mg bd

Bumetanide 2 mg bd

Digoxin 125 micrograms od

Sildenafil 50 mg od prn

Spironolactone stopped due to rising Creat and K+

Transplant referral (continued smoking, DNA)

Admitted, UTI, AKI, inotropes, CVVH



**Choked whilst
awaiting transfer**

Martin, 39



Prepare for transplant earlier
do catheter early

EOL conversations earlier
when referring for transplant, have parallel care
and conversations

Renal dysfunction not a barrier if improves on inotropes

Steve, 32

Transposition of the great arteries

Mustard repair

Coarctation of the aorta

Moderate systemic ventricular impairment

Moderate tricuspid regurgitation

Endocarditis, 1999

Nodal rhythm with atrial tachycardia/flutter (1999, 2000, x2 2008, 2012
requiring
cardioversion)

?for CRT +/- ablation

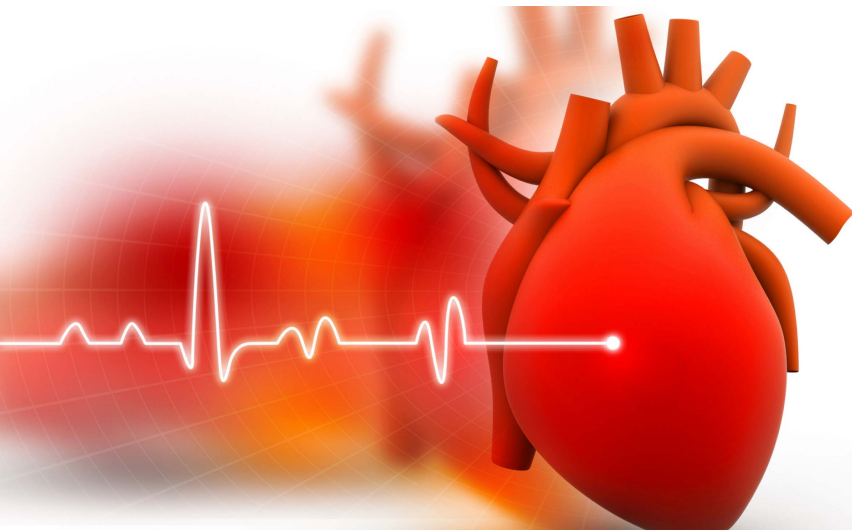


Sudden cardiac death

**Mean age at death
40-49 yrs**

SCD 20%

**Heart failure
27%**



Verheugt CL. Eur Heart J. 2010 May;31(10):1220-9
Greutmann et al, (2014). Congenital Heart Disease, 10 (2);117-127
Engelings CC. Int J Cardiol. 2016 May 15;211:31-6



Sally, 21

Left atrial isomerism

Common atrium with complete AVSD and small ventricular component

Left SVC to coronary sinus

Azygous continuation of IVC to right SVC

Repair of common atrium 1995

Residual ASD

Left AV valve repair (Alfieri) and closure of residual ASD 2001

PPM 1997 (upgrade to DDD 2002)

Pulmonary embolism and right atrial thrombus 2009


Pulmonary hypertension

Atrial tachycardia

Pulmonary haemorrhage 2011 and 2014 (embolisation)



LRTI

A background image showing several autumn leaves in shades of yellow, orange, and red, scattered across a light blue and white gradient. The leaves are in various stages of fall, with some showing vibrant colors and others appearing more faded or blurred.

**How do we
manage
death?**

PUGH



*'But mum, I'm
nearly seventeen'*

Sarah, 25

Coarctation of the aorta (end to end anastomosis 1993)

Congenital mitral valve stenosis with supramitral ring (excised 1996 with commissurotomy)

Severe mitral stenosis (abnormal CPET, no symptoms)

Wants to get pregnant

Biological mitral valve prosthesis (25 mm Perimount), February 2016

Patient prosthesis mismatch

Gets pregnant!

Bioprosthetic valve deterioration

mild stenosis (small valve)

moderate to severe regurgitation



**What do patients
(and parents)
want to hear?**



Anna, 18

**Middle aortic syndrome
Hypertension**

**Clinic discussion about
pregnancy**



Earlier transplant referral

Parallel care

Earlier EOL discussions

Think about SCD risk

Sensitivity around parents

Care discussing pregnancy and surgery with young adults

Good communication

